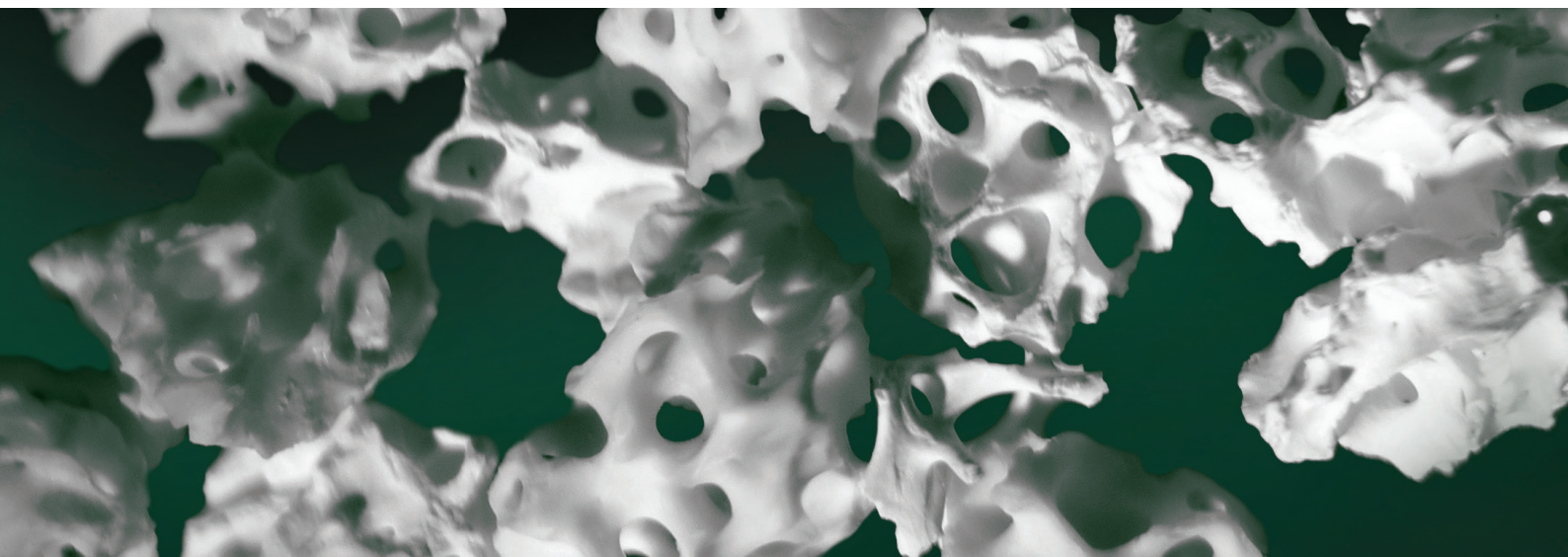

Ti-oss[®] resorption by Osteoclast found on 8 weeks rat model.

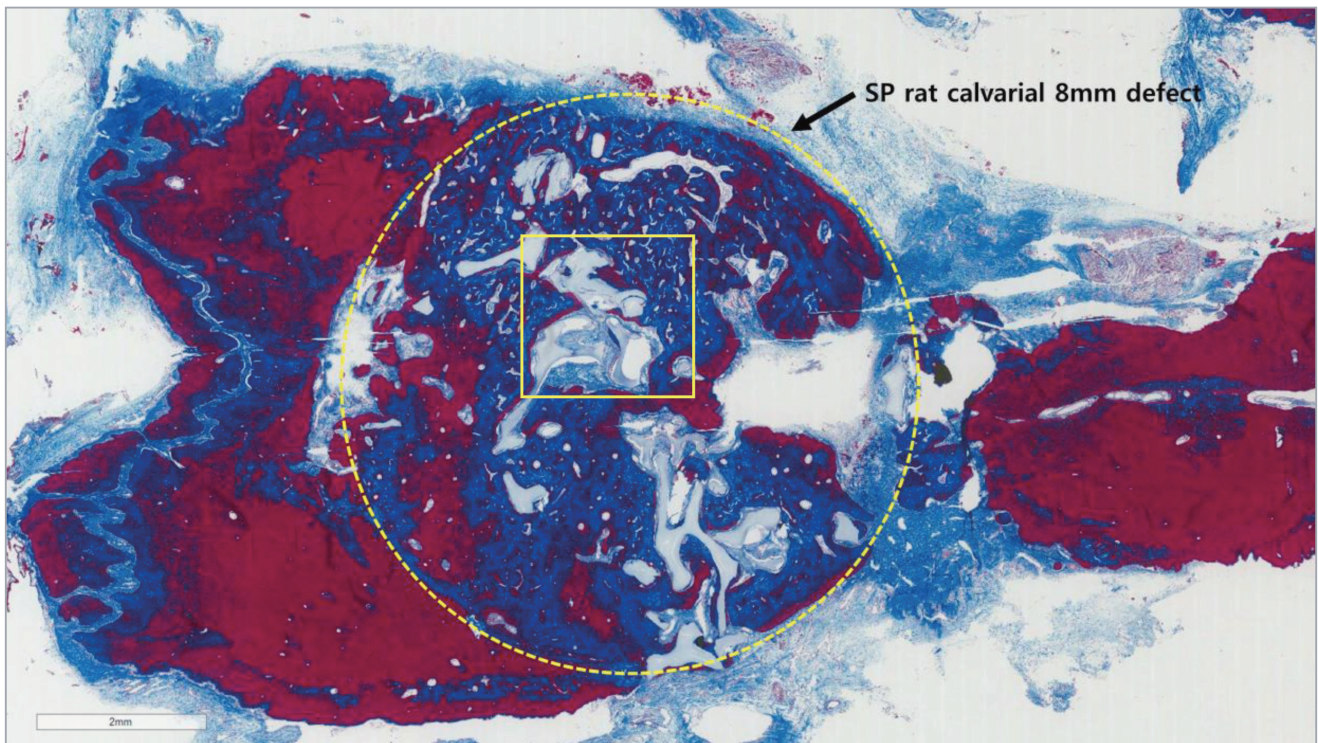
Korea University Hospital, Dental Division
Oral and maxillofacial department

Jun, Sangho, DDS

May, 2015

Ti-oss[®] resorption by Osteoclast found on 8 weeks rat model.

In 8 weeks after the placement of Ti-oss[®] bone graft, rat calvarial defect has been filled into the defect center.



Ti-oss[®] resorption by Osteoclast started 8 weeks after the placement of Ti-oss[®] graft onto the surgical defect. (yellow square)

